

ACL reconstruction associated with lateral extra-articular tenodesis with shared femoral tunnel

Lucas Vieira,¹ Lúcio Sergio Rocha Ernlund,² Jonathan Buiar Vidal³

1. Sports Medicine Surgeon at the Knee and Shoulder Institute, Curitiba, PR, Brazil
Coordinator of the Orthopedics Department at the INC Hospital, Curitiba, PR, Brazil

2. Sports Medicine Surgeon at the Knee and Shoulder Institute, Curitiba, PR, Brazil
Medical Director of the Knee and Shoulder Institute, Curitiba, PR, Brazil

3. Knee Surgeon at the Knee Clinic, Curitiba, PR, Brazil

SUMMARY

Recently, the anterolateral ligament has gained attention in knee surgery for its ability to improve rotational stability in ACL reconstructions. However, the lateral extra-articular tenodesis (LET) procedure, which involves creating a femoral tunnel using the modified Lemaire technique, presents a risk of overlapping with the femoral tunnel used in the ACL reconstruction. This can lead to complications and limit the success of the surgery. To avoid these issues without needing additional fixation, we describe an easily reproducible surgical technique in which a single femoral tunnel is shared for both ACL reconstruction and LET using the iliotibial tract.

Keywords: Knee joint; Anterior cruciate ligament; Tenodesis

RESUMEN

Recientemente, el ligamento anterolateral ha ganado atención en la cirugía de rodilla por su capacidad para mejorar la estabilidad rotacional en las reconstrucciones del LCA. Sin embargo, el procedimiento de tenodesis lateral extraarticular (TLE), que implica la creación de un túnel femoral utilizando la técnica modificada de Lemaire, presenta un riesgo de solapamiento con el túnel femoral utilizado en la reconstrucción del LCA. Esto puede provocar complicaciones y limitar el éxito de la cirugía. Para evitar estos problemas, sin necesidad de una fijación adicional, describimos una técnica quirúrgica fácilmente reproducible en la que se comparte un solo túnel femoral tanto para la reconstrucción del LCA como para LET utilizando el tracto iliotibial.

INTRODUCTION

The anterolateral ligament (ALL) has become increasingly significant in knee surgery in recent years.¹ This triangular structure is located deep to the iliotibial tract, and it originates proximally at the lateral epicondyle of the femur and distally inserts into the tibia between Gerdy's tubercle and fibula.² The role of the ALL in providing rotational stability to the anterolateral aspect of the knee has been well established.^{1,3}

To improve clinical outcomes and reduce the incidence of re-injuries, lateral extra-articular tenodesis (LET) and ALL reconstruction have been performed in conjunction with classic ACL reconstruction. Biomechanical studies have demonstrated that combining these procedures can restore knee kinematics, increase the success rate of meniscal repairs (when necessary), and lower the rate of ACL re-injuries.⁴ Moreover, clinical evidence has already shown that combining these procedures leads to a lower prevalence of residual pivot shift and better clinical outcomes.⁵

The use of techniques that address the ALL in combination with ACL reconstruction is mainly indicated for ACL reconstruction revision surgeries, patients with an explosive pivot shift, and patients who have engaged in sports involving pivot shift movements. Additionally, these techniques are indicated for cases of Segond and/or impaction fractures of the lateral femoral condyle.^{1,6}

When performing LET using the modified Lemaire technique in conjunction with ACL reconstruction, there is a risk of the femoral tunnels convergence. This can compromise the graft integration or fixation, lead to fractures, or even result in osteonecrosis of the femoral condyle. An alternative to address this problem is to use anchors in the femoral fixation of the tenodesis.^{3,5} To reduce this risk and avoid the use of additional fixation materials, we describe a surgical technique in which the femoral tunnel is shared for fixation of the ACL and LET using the iliotibial band.

SURGICAL TECHNIQUE DESCRIPTION

The patient is positioned in a supine position on the operating table with a pneumatic tourniquet placed at the root of the thigh to be operated on. A lateral and a foot support are used to facilitate the knee flexion position.

Lucas Vieira

lucasvieiracb@gmail.com

Recibido: Marzo de 2023. Aceptado: Marzo de 2023.

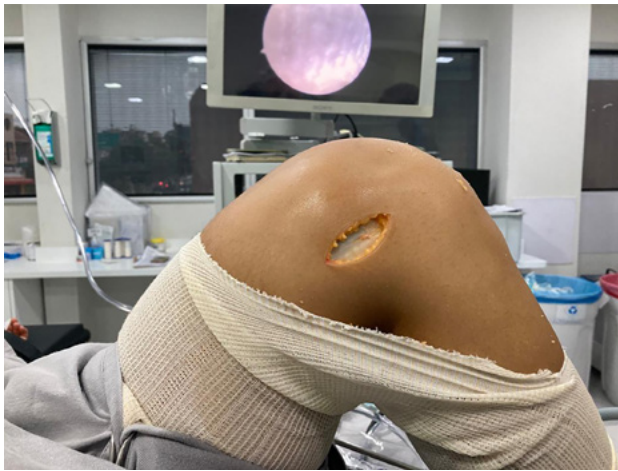

Figure 1: Lateral access to right knee.

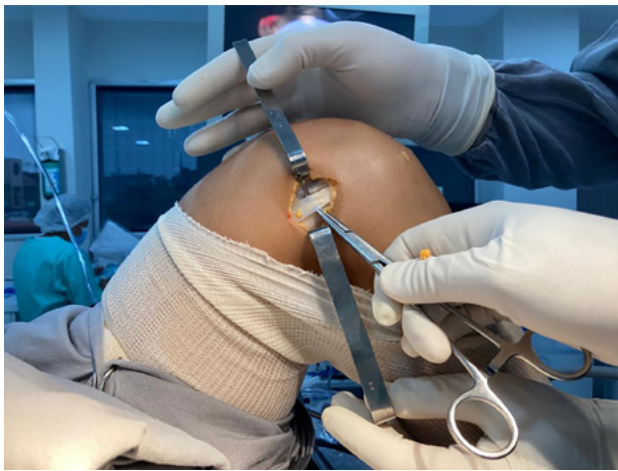

Figure 2: Dissection of iliotibial tract to be used in lateral extra-articular tenodesis of the knee.

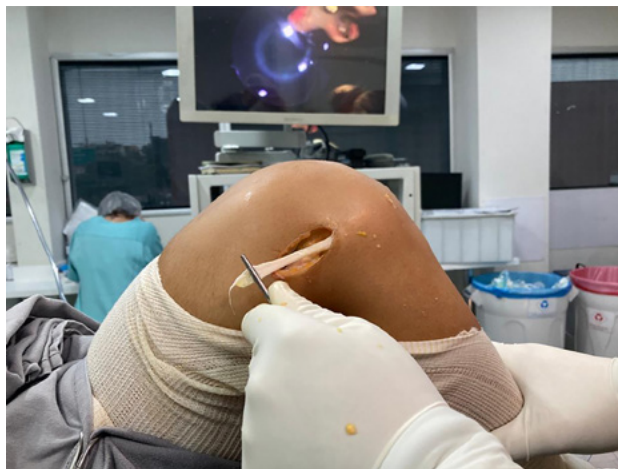

Figure 3: Dissection of iliotibial tract to be used in lateral extra-articular tenodesis of the knee, with detachment of its proximal portion.

Routine preparation for orthopedic surgery is carried out.

After harvesting the graft to be used in ACL reconstruction, arthroscopy of the knee is performed to identi-

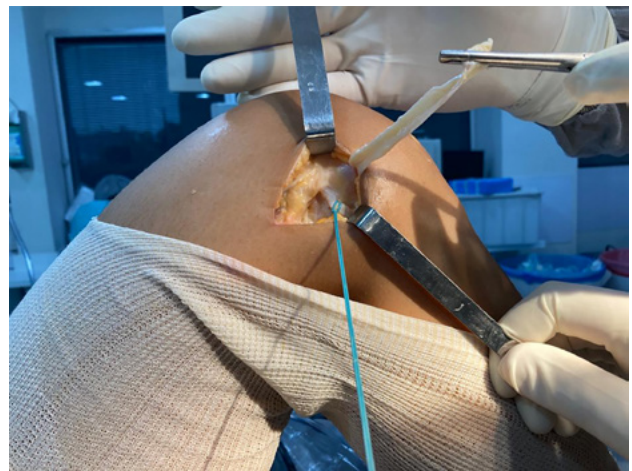

Figure 4: Lateral collateral ligament repaired with suture wire after its identification, and iliotibial tract repaired by forceps away from the surgical field for better visualization.

fy and treat any associated injuries, as well as to identify anatomical landmarks for ligament reconstruction. The procedure involves making anterolateral, medial parapatellar, and accessory medial portals for arthroscopy, which allows for optimal visualization and access to the knee joint.

A longitudinal incision of approximately 5-7 cm is made on the lateral aspect of the knee, based on palpation of the lateral epicondyle (fig. 1).

The subcutaneous tissue is dissected, and the iliotibial tract is identified. A strip of the central-posterior region of the iliotibial tract, approximately 8-10 mm in thickness, is demarcated, leaving the posterior fibers inserted into the femur intact (fig. 2).

In the proximal region, this strip is detached from the iliotibial tract, approximately 60-80 mm in length. Distally, it is released from the iliotibial tract, but its insertion in the proximal region and side of the tibia, close to Gerdy's tubercle, is maintained (fig. 3). At the free end, an absorbable suture is used.

Deep to the iliotibial band, the lateral collateral ligament (LCL) is identified after local dissection (fig. 4).

It is important to be careful not to violate the joint. After identifying the LCL and its femoral insertion, the lateral epicondyle is identified. The location for making the combined femoral tunnel for the reconstruction of the ACL and the LET is identified posterior and proximal to the lateral epicondyle.

Using the ACL guide device, the guide wire for the shared femoral tunnel is passed from outside to inside, starting from the point identified earlier posterior and proximal to the lateral epicondyle, and ending at the anatomical origin of the ACL on the medial aspect of the lateral condyle (fig. 5)

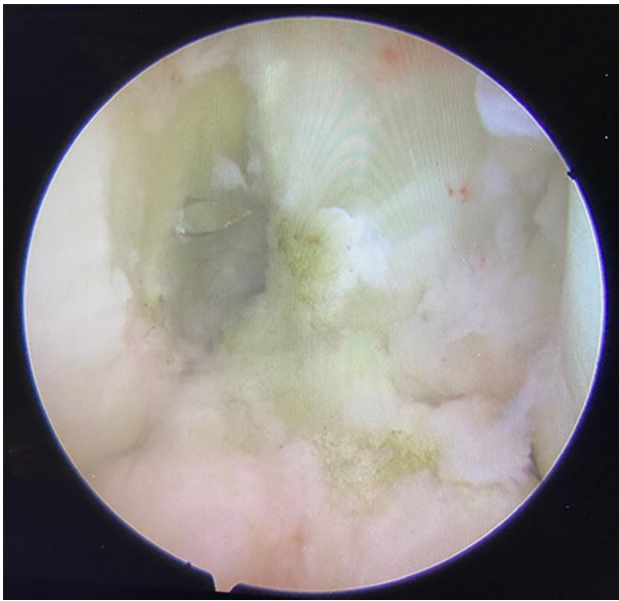

Figure 5: Arthroscopic view through medial portal of guide wire for creating shared tunnel at femoral anatomical point of anterior cruciate ligament.

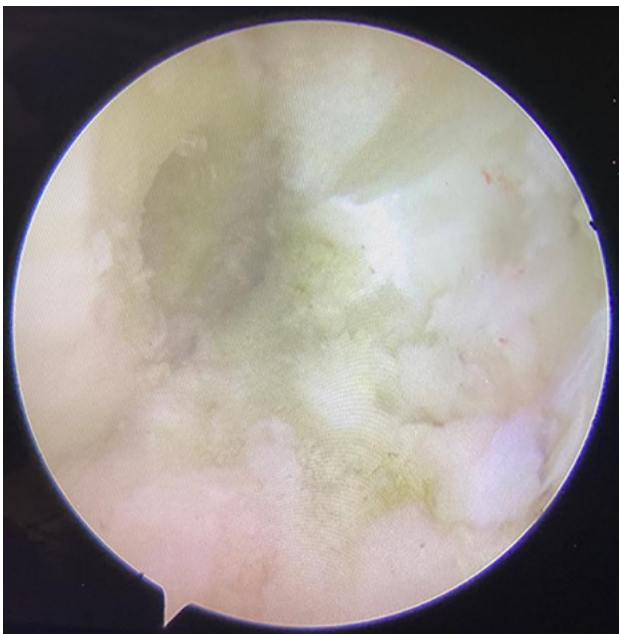


Figure 6: Arthroscopic view through medial portal of shared tunnel at femoral anatomical point of anterior cruciate ligament.

Arthroscopic visualization of the joint is achieved through the accessory medial portal, while the articular component of the guide is inserted through the medial parapatellar portal. Once the guide wire is properly positioned, the tunnel is drilled to a diameter 1 mm larger than the graft to be used in ACL reconstruction (figs. 6 and 7). A curette is used to prevent the wire and drill from migrating into the joint. Finally, the tibial tunnel is drilled in a standard fashion.

The strip of iliotibial tract is passed underneath the

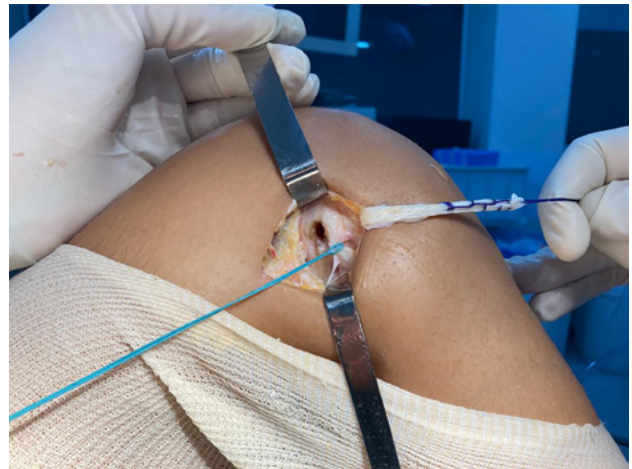

Figure 7: Shared tunnel created posterior and proximal to lateral epicondyle. Lateral collateral ligament repaired with suture wire, and iliotibial tract repaired with its suture for tenodesis.

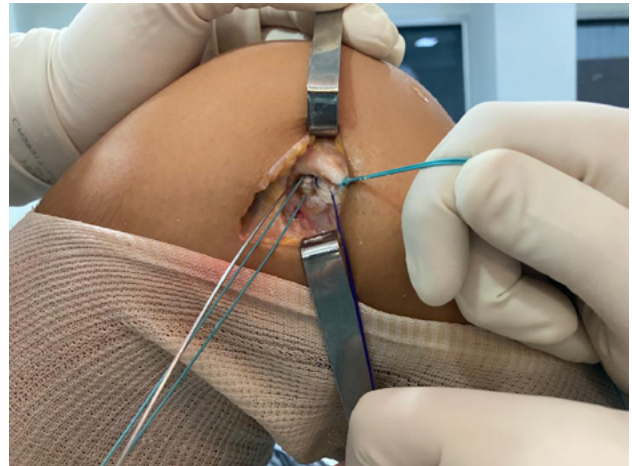


Figure 8: Graft for anterior cruciate ligament reconstruction and iliotibial tract for lateral extra-articular tenodesis already positioned in shared femoral tunnel, with interference screw guide wire in proximal region. Lateral collateral ligament.

LCL using a grasper forceps, and its suture is then threaded through the shared tunnel and into the joint region, where it is inserted into the shared femoral tunnel. The suture is then pulled through the accessory medial portal. Next, the guide wire for the interference screw used for femoral fixation is inserted from outside the knee and directed into the most proximal position of the shared tunnel.

The ACL graft is then passed through the tibial tunnel and into the shared femoral tunnel, until it is visible through the lateral aspect of the knee (fig. 8).

The position of the graft and tenodesis should be verified, and then they should be fixed with a single interference screw that has the same diameter as the shared femoral tunnel and placed in the most proximal part of the tunnel. This allows for maximum contact between the

ACL graft, tenodesis, and the bone tunnel walls (fig. 9).

The proximal and distal sutures of the ACL graft are gently pulled to prevent it from moving during screw fixation, while the tenodesis is pulled through its suture from the accessory medial portal. It is important to ensure that the knee is in a neutral rotation position and flexed at about 30° during this process.

After femoral fixation, conventional distal fixation of the ACL graft on the tibia is performed. The tenodesis suture is cut intra-articularly using a basket-shaped forceps. The iliotibial tract is sutured with absorbable thread. The subcutaneous tissue and skin are closed using standard techniques.

DISCUSSION

The addition of LET in ACL reconstructions is indicated for improved rotational control of the knee, leading to a reduction in the pivot shift and better clinical outcomes when deemed appropriate.^{3,6}

However, this procedure can also carry risks such as the convergence of the femoral tunnels, which can compromise the stability of the graft fixation. More complex situations such as condyle fracture or osteonecrosis have also been reported.³ To minimize these complications, the LET tunnel should be kept shorter, around 15 mm, and made with a minimum anterior inclination of 20-30°. Alternatively, a tenodesis fixation using anchors can be performed to avoid the use of tunnel.^{3,5}

The technique we describe has the advantage of avoiding tunnel convergence by using a single shared tunnel for both ACL reconstruction and LET. The tunnel exits at the anatomical point of the anterior cruciate ligament on the femur and originates on the lateral femoral cortex at the insertion of the tenodesis, proximal and posterior to

the lateral epicondyle. This shared tunnel allows for a longer length, which promotes better integration of the lateral extra-articular tenodesis.

Espejo-Reina *et al.*⁷ described a similar surgical technique for cases in which the diameter of the flexor tendons is considered insufficient. They used a longer iliotibial tract graft passed from outside to inside of the femur to the tibial tunnel, performing an augmentation of the flexor graft in ACL reconstruction. However, in our technique, LET fixation occurs in the usual femoral region without the need for the iliotibial tract graft to reach the distal region of the tibial tunnel, allowing for smaller access and less aggression to the iliotibial tract region.

Our technique may also be indicated in revision ACL reconstructions that involve lateral extra-articular tenodesis when the femoral tunnel used in the primary surgery is dilated. This is because the graft fixation occurs mainly from the outside to the inside. Additionally, it can be combined with any type of graft used in ACL reconstruction.

Another advantage of this technique is that there is no need to use a third interference screw or anchors, which can reduce surgical costs, an important consideration in our context.

FINAL CONSIDERATIONS

In conclusion, we believe that our technique is easy to replicate, does not add significant time to surgery, and avoids the potential complications associated with ACL reconstruction surgery combined with LET. Additionally, it does not require the use of additional fixation materials, which can reduce surgical costs. We hope that our approach can be useful in clinical practice, providing better outcomes for patients undergoing ACL reconstruction with LET.

REFERENCES

- Ariel de Lima D; Helito CP; Lima FRA; Leite JAD. Surgical indications for anterior cruciate ligament reconstruction combined with extra-articular lateral tenodesis or anterolateral ligament reconstruction. *Rev Bras Ortop*, 2018; 53(6): 661-7.
- Helito CP; Demange MK; Bonadio MB; Tírico LE; Gobbi RG; Pécora JR; Camanho GL. Anatomy and histology of the knee anterolateral ligament. *Orthop J Sports Med*, 2013; 1(7): 2325967113513546.
- Perelli S; Erquicia JI; Ibañez M; Daesino G; Gelber PE; Pelfort X; Monllau JC. Evaluating for tunnel convergence in anterior cruciate ligament reconstruction with modified Lemaire tenodesis: what is the best tunnel angle to decrease risk? *Arthroscopy*, 2020; 36(3): 776-84.
- Jacquet C; Pioger C; Seil R; Khakha R; Parratte S; Steltzlen C; Argenson JN; Pujol N; Ollivier M. Incidence and risk factors for residual high-grade pivot shift after ACL reconstruction with or without a lateral extra-articular tenodesis. *Orthop J Sports Med*, 2021; 9(5): 23259671211003590.
- Zhu M; Han Lee DY; Williams A. Safe femoral fixation depth and orientation for lateral extra-articular tenodesis in anterior cruciate ligament reconstruction. *Orthop J Sports Med*, 2021; 9(1): 2325967120976591.
- Getgood AMJ; Bryant DM; Litchfield R; Heard M; McCormack RG; Rezanoff A; Peterson D; Bardana D; MacDonald PB; Verdonk PCM; Spalding T e STABILITY Study Group; Willits K; Birmingham T; Hewison C; Wanlin S; Firth A; Pinto R; Martindale A; O'Neill L; Jenning. Lateral extra-articular tenodesis reduces failure of hamstring tendon autograft anterior cruciate ligament reconstruction: 2-year outcomes from the STABILITY Study Randomized Clinical Trial. *Am J Sports Med*, 2020; 48(2): 285-97.
- Espejo-Reina A; Espejo-Reina MJ; Lombardo-Torre M; Ruiz-Del Pino J; Espejo-Baena A. Anterior cruciate ligament reconstruction using combined graft of hamstring and fascia lata with extra-articular tenodesis. A technique in case of insufficient hamstrings. *Arthrosc Tech*, 2020; 9(11): e1657-e1663.